

Differentiation of serrated and non-serrated blades from stab marks in bone.

Thompson, TJU* and Inglis, J.

School of Science & Technology, University of Teesside, Borough Road,
Middlesbrough, Cleveland, UK. TS1 3BA

*author for correspondence.

Abstract

Although evidence of sharp force trauma on the human body, particularly the skeleton, can be extremely useful in providing information regarding the manner and context of death, there is still a lack of necessary detail available to the investigator. Using ribs, radii, scapulae, vertebrae and carpal bones this study demonstrated that distinctions could be made between the stab marks left by serrated blades and those of non-serrated blades. Low power and scanning electron microscopy were used to record distinctive 'T' shaped stabmarks from non-serrated blades and 'Y' shaped stabmarks from serrated blades. In addition, elemental evidence of the presence of the blade in the stabmark kerf was recoverable even when no metal fragment was visible.

Keywords

Forensic anthropology; sharp force trauma; stabbing; cut mark; SEM

Introduction

Sharp force trauma has long been argued to be the most frequent cause of murder in the United Kingdom [1, 2, 3]. Successful analysis and interpretation can provide important contextual information regarding the instant of trauma, such as the position of the victim in relation to the attacker, the handedness of the attacker, whether the wound was caused by suicide or homicide etc. [for example 2, 4, 5, 6, 7]. Furthermore, the motion of the sharp object can be ascertained depending on whether a cut (the incision is wider than it is deep) or stab (the incision is deeper than it is wide) mark is left [see 8 for trauma definitions]. Although the sharp object must pass through the soft tissues first, it is often the hard tissues that best record and preserve the impression of the weapon; indeed they will be the only record after decomposition. Previous work has focussed on interpreting sharp-force trauma from bone in order to make statements about the context of death in both forensic and archaeological contexts. Such work includes the definition of kerf dimensions and properties [9, 10], the differentiation of cutmark origin [9, 10, 11, 12, 13, 14], the impact of other taphonomic processes on cutmark preservation [15, 16], patterns of butchery and dismemberment [10, 17, 18, 19] and describing the details of the trauma incident itself [1, 2, 4, 5, 6, 7, 20, 21]. Although research has demonstrated that it is possible to distinguish the class of sharp object used from the mark left behind, it is difficult to be any more precise than that. There are times, however, when this would be of great use. Specifically, it would be of use to be able to separate stab marks made by a non-serrated blade, and those made by a similar, but serrated blade.

Due to its general resistance to decomposition, bone often preserves the evidence of a sharp-force weapon attack a great deal longer than the soft tissues. Nonetheless, it is often useful to collect a cast or replica of the cut-mark in order to protect the original specimen. A number of studies have attempted to determine the most appropriate casting medium for this. In addition, casts have been attempted on soft tissue cutmarks with some success [22]. Some work has examined the force necessary to penetrate the soft tissues [1, 3], but other than the work of Kieser et al. [14], no attempt has been made to determine the relationship between cut marks in soft tissue and the underlying hard tissue.

Although it is entirely possible to view such marks with the naked eye, or using standard photography, scanning electron microscopy (SEM) has become the method of choice for analysing such cutmarks. Scanning electron microscopy provides a high resolution magnified image of the surface of the element of interest and has been widely accepted as a standard tool in forensic science and in cut-mark analysis [see 9, 10, 11, 12, 13 for its deployment in this context].

Therefore the aim of this research was to ascertain the difference between marks left by serrated and non-serrated blades in an attempt to provide the forensic pathologist, anthropologist and investigator with additional information regarding the context and manner of death.

Methods and materials

Ribs, radii, scapulae, vertebrae and carpal bones were used in this experiment because, despite their different structures, all have a known ability to record cut-marks, in addition to being sites of stabbing in forensic cases recorded in the literature [e.g. 2, 4, 5, 6]. Pig bones were used because of their acknowledged similarity to human bones. Pig bones have a long history of use in trauma and taphonomic studies in anthropology. Both the non-serrated and serrated knives were made by the same manufacturer (Prestige) and originate from the same product range. This was chosen in order to reduce the effect of variables other than blade style. The knives had a width of 2.3cm and a length of 20cm. The teeth on the serrated knife were 0.2cm long and 0.6cm apart. The knives used in this work were new.

The bones were defleshed in warm water using a biological detergent. The bones were held in place on the work-surface with a clamp to ensure consistent positioning amongst all samples, and to restrict movement upon impact. The researcher (JI) wore appropriate protective clothing and struck the bones with the knife using her right arm. Three marks were made, and speed and force of blow was kept as consistent as reasonably possible. The marks were examined using the naked eye, a low-powered microscope and an environmental scanning electron microscope. The environmental SEM does not require sample preparation, and allows the user to examine bone samples free of a gold or carbon coating. As such, this technique is non-destructive and arguably more precise than traditional methods. Furthermore, it has been used in previous research of this nature [14].

In addition to recording the shape and size parameters of the stab mark, an attempt was made to assess the degree of damage to the kerf. For this, a subjective 5-point scale was used with 0 equalling no damage and 5 representing extensive damage.

Results

The main results of the visual, low-powered and scanning electron microscopy are presented in Tables 1, 2 and 3 respectively. The values presented are mean averages. It can be seen from Table 1 that on average the serrated blade produces longer and narrower stab marks than the non-serrated blade. In addition, the degree of damage is also greater. With both knife types, damage was greater in those elements with a high degree of cancellous bone. These trends are, as one would expect, repeated in Tables 2 and 3. Although the average values for length and width do not vary significantly between Tables 1, 2 and 3, the values for kerf damage do. This is because the greater magnification allows one to appreciate more subtle damage patterns.

Figures 1, 2 and 3 show representative examples the stab mark shapes referred to in Tables 1, 2 and 3. It can be seen that the marks are indeed different for both the non-serrated and serrated blades, that these differences are consistent throughout all specimens and that the differences can be seen at all three viewing magnifications.

In addition to utilising the SEM to examine the surface of the stab mark, an elemental analysis (Elemental Dispersive Spectroscopy – EDS) was undertaken. This technique allows the elements (and their abundance) on the surface of a material to be determined. The results of this assessment are presented in Table 4.

Discussion

Despite the frequency of knife-related injuries and deaths in the United Kingdom and elsewhere, there is a paucity of research in this area. As such, it can be difficult to extrapolate even the most basic information from a cut or stab mark. That said, a very clear pattern has emerged from the data in this study (Figures 1, 2 and 3). The non-serrated blade consistently produced a well defined ‘T’ incision surrounded by a triangular region of depressed compact bone. The serrated knife produced a ‘Y’ shaped incision, surrounded by a triangular region of depressed bone but with a right lateral curve to the tail of the incision. The ‘T’-shaped stab mark from the non-serrated blade is consistent with that produced by Thali et al. [23] from a similar weapon. The differences in shape of stab mark seems to result from the fact that the non-serrated blade causes bevelling of the bone laterally to the blade, while the serrated blade causes a single bevel superior to the blade. Thus, on average, the ‘Y’ shaped feature appears longer and narrower than the ‘T’ shaped mark (Tables 1, 2 and 3). That said, these results are in agreement with Humphrey and Hutchinson who argue that sharp weapons cause little crushing and fracturing [12].

The lateral kink in the tail of the serrated blade is of interest. Repeated experimentation using the opposite hand (left, instead of right) still produced the feature, thus strongly indicating that the weapon itself is the cause of the lateralisation. Figure 4 shows the cross-section of the blade and from this it can be seen that the cutting edge of the serrated blade is offset laterally compared to the non-serrated blade.

It has also been demonstrated that the definition of the stab mark varies depending on the amount of cancellous bone present at the incision site. Greater relative quantities of cancellous bone allow for clearer definition of the resultant mark. In practice, this will affect the ability to distinguish the subtle differences between non-serrated and serrated blades. The surface of a blade can also result in striations on the kerf wall that can be related to saw or knife class [14, 24] although one would also expect this to be affected by the ratio of cancellous to compact bone at the cutmark site.

There are two main weaknesses to this study. First, as is common in such experimental trauma studies, there is the fact that the sample size is relatively small. Further work is recommended here, although the consistency of the stab mark shape differences across bone types and morphologies suggests that we can be confident about the conclusions. Second, the marks were made with minimal soft tissue present. It is important that we investigate whether these features are present, or as clear, on the hard tissues when the knife must penetrate the soft tissues first.

It is entirely possible for fragments of a blade to be deposited within the cutmark following an attack [23, 25]. Unfortunately the results of the Scanning Electron Microscope – Elemental Dispersive Spectroscopy analysis (Table 4) performed at the conclusion of this research proved inconclusive. The presence of iron, silicon and aluminium were detected within the stab mark however it was impossible to fully rule out the influence of sample contamination. Although this technique has been used successfully in the forensic and osteological context [25], our experiences should be viewed as a warning to the potential undermining problems of this approach to stab and cutmark investigation.

Conclusions

It can be seen that the specific nature of the knife using in an attack can be determined beyond just single or doubled edged. It is now possible to determine whether the stab originated from a non-serrated or serrated blade. Furthermore, results suggest that applying EDS methods to cutmarks during the standard SEM analysis phase may yield potentially useful information about the weapon of choice. There is still much work that needs to be undertaken in this field, but this research adds more information which may help the forensic practitioner in lethal stabbing contexts.

Acknowledgements

We would like to thank our fellow Forensic Biology Research Kernel members for their support and help throughout this project. Ken Robinson provided much assistance with the SEM. Dr Becky Gowland (Durham University) gave very useful comments and suggestions on earlier drafts of this paper.

References

1. Knight B (1975) The dynamics of stab wounds. *Forensic Sci* 6:249-255
2. Hunt AC, Cowling RJ (1991) Murder by stabbing. *Forensic Sci Int* 52:107-112
3. Hainsworth SV, Delaney RJ, Ruddy GN (2008) How sharp is sharp? Towards quantification of the sharpness and penetration ability of kitchen knives used in stabbings. *Int J Legal Med* doi 10.1007/s00414-007-0202-6
4. Ormstad K, Karlsson T, Enkler L, Law B, Rajs J (1986) Patterns in sharp force fatalities – a comprehensive forensic medical study. *J Forensic Sci* 31:529-542
5. Bamasr A, Grandmaison GL de la, Durigon M (2003) Frequency of bone/cartilage lesions in stab and incised wounds fatalities. *Forensic Sci Int* 131:131-133
6. Schmidt U, Pollak S (2006) Sharp force injuries in clinical forensic medicine – findings in victims and perpetrators. *Forensic Sci Int* 159:113-118
7. Karger B, Vennemann B (2001) Suicide by more than 90 stab wounds including perforation of the skull. *Int J Legal Med* 115:167-169
8. Ruddy GN (2007) Soft tissue trauma. In: Thompson TJU, Black SM (eds) *Forensic human identification: an introduction*. CRC Press, Boca Raton, Florida, pp 113-126
9. Bartelink EJ, Wiersema JM, Demaree RS (2001) Quantitative analysis of sharp-force trauma: an application of scanning electron microscopy in forensic anthropology. *J Forensic Sci* 46:1288-1293

10. Bello SM, Soligo C (2008) A new method for the quantitative analysis of cutmark micromorphology. *J Arch Sci* doi:10.1016/j.jas.2007.10.018
11. Alunni-Perret V, Muller-Bolla M, Laugier J-P, et al. (2005) Scanning electron microscopy analysis of experimental bone hacking trauma. *J Forensic Sci* 50:1-6
12. Humphrey JH, Hutchinson DL (2001) Macroscopic characteristics of hacking trauma. *J Forensic Sci* 46:228-233
13. Saville PA, Hainsworth SV, Ritty GN (2007) Cutting crime: the analysis of the “uniqueness” of saw marks on bone. *Int J Legal Med* 121: 349-358
14. Kieser J, Bernal V, Gonzalez et al. (2008) Analysis of experimental cranial skin wounding from screwdriver trauma. *Int J Legal Med* 122: 179-188
15. Herrmann NP, Bennett JL (1999) The differentiation of traumatic and heat-related fractures in burned bone. *J Forensic Sci* 44:461-469
16. De Gruchy S, Rogers TL (2002) Identifying chop marks on cremated bone: a preliminary study. *J Forensic Sci* 47:933-936
17. Outram AK, Knüsel CJ, Knight S, Harding AF (2005) Understanding complex fragmented assemblages of human and animal remains: a fully integrated approach. *J Archaeol Sci* 32:1699-1710
18. Pickering TR, Egeland CP (2006) Experimental patterns of hammerstone percussion damage on bones: implications for inferences of carcass processing by humans. *J Archaeol Sci* 33:459-469
19. Konopka T, Bolechala F, Strona M (2006) An unusual case of corpse dismemberment. *Am J Forensic Med Pathol* 27:163-165

20. Patrick P (2006) Approaches to violent death: a case study from Early Medieval Cambridge. *Int J Osteoarchaeol* 16:347-354
21. Knüsel CJ, Outram AK (2006) Fragmentation of the body: comestibles, compost, or customary rite? In: Gowland R, Knüsel CJ (eds) *Social archaeology of funerary remains*. Oxbow Books, Oxford, UK, pp 253-278
22. Rawson RB, Hansen Starich G, Rawson RD (2000) Scanning electron microscopic analysis of skin resolution as an aid in identifying trauma in forensic investigations. *J Forensic Sci* 45: 1023-1027
23. Thali MJ, Taubenreuther U, Karolczak M, Braun M, Brueschweiler W, Kalender WA, Dirnhofer R (2003) Forensic microradiology: micro-computed tomography (Micro-CT) and analysis of patterned injuries inside of bone. *J Forensic Sci* 48:1336-1342
24. Bonte W (1975) Tool marks in bone and cartilage. *J Forensic Sci* 20:315-323
25. Bajanowski T, Kohler H, Schmidt PF et al. (2000) The cloven hoof in legal medicine. *Int J Legal Medicine* 114: 346-348

Table and Figure Legends

Table 1: Stab mark details as viewed by the naked eye.

Table 2: Stab mark details as viewed by low-powered microscopy.

Table 3: Stab mark details as viewed by scanning electron microscopy.

Table 4: Elemental analysis of the stab marks and knives.

Figure 1: Stab marks from serrated (upper) and non-serrated (lower) blades in rib bone.

Figure 2: Stab marks from serrated (upper) and non-serrated (lower) blades in the spinous processes of vertebral bone.

Figure 3: Stab marks from serrated (upper) and non-serrated (lower) blades in the spinous processes of vertebral bone as seen using SEM.

Figure 4: Cross-section of knife blades, as seen from the tip.













	Shape	Length (mm)	Width (mm)	Kerf damage	Fragmentation / fractures	
Serrated blade	Rib		5.00	1.00	3	Some fractures around bottom of the mark
	Radius epiphysis		6.00	1.00	2	—
	Radius diaphysis		1.75	0.63	1	Chunk of kerf lifted out to the left
	Scapula		3.50	0.75	1	Large fragmentation if 2 marks in close proximity
	Vertebra		3.67	1.00	1	Some fracturing
	Carpal		2.67	0.75	2	Small fragmentation of kerf
	Mean		5.90	0.85	1.7	—
Non-serrated blade	Rib		9.50	0.92	2	1 fracture towards bottom left of mark
	Radius epiphysis		2.33	0.75	2	—
	Radius diaphysis		1.33	0.83	1	Chunk of kerf lifted out
	Scapula		9.0	1.50	1	Some fracturing
	Vertebra		3.33	1.17	2	Small fragmentation of kerf
	Carpal		3.67	1.00	1	—
	Mean		4.86	1.03	1.5	—

Table 1













	Shape	Length (mm)	Width (mm)	Kerf damage	Fragmentation / fractures
Separated blade		3.43	0.88	3	Ruffling and some fragmentation of kerf
		5.53	1.02	3	Kerf gouged out to the left of the mark
		1.81	0.65	2	—
		18.54	0.73	2	Fragmentation of other side
		3.65	0.72	2	Small fractures at top causing Y shape
		1.23	0.50	3	Fracture of the mark's tail and fragmentation of kerf
	Mean		5.94	0.75	2.5
Non-separated blade		3.87	0.66	2	2 fractures either side of top giving a T shape. 1 fracture on bottom left of tail
		2.53	0.88	3	Kerf gouged out to the left of the mark
		1.54	0.73	1	—
		9.09	1.38	3	Ruffling of kerf and several small fractures. Fragmentation of back
		2.71	0.78	3	Small fragmentation of kerf
		3.14	0.60	2	—
	Mean		3.81	0.84	2.3

Table 2













	Shape	Length (mm)	Width (mm)	Kerf damage	Fragmentation / fractures	
Serrated blade	Rib		3.44	0.88	4	Fragmented kerf and fractures around the side of the mark
	Radius epiphysis		5.60	1.02	2	—
	Radius diaphysis		1.82	0.65	3	Torn and fragmented kerf
	Scapula				2	—
	Vertebra		3.69	0.72	2	Small fragmentation
	Carpal		2.69	0.50	3	Kerf Ruffled & torn. Fractures at top producing Y shape
	Mean		5.77	0.75	2.7	
Non-serrated blade	Rib		3.91	0.66	3	Torn & fragmented kerf
	Radius epiphysis		2.53	0.88	3	Torn and ruffled kerf
	Radius diaphysis		1.56	0.73	4	Kerf gouged to the left of the mark
	Scapula				3	—
	Vertebra		2.76	0.78	2	Lots of fragmentation of kerf and inside material. Fracture top right of mark
	Carpal		3.09	0.60	4	Kerf very ruffled & torn. Lots of fragmentation inside mark
	Mean		3.84	0.84	3.2	

Table 3

<u>Sample</u>	Elements confirmed	
	Serrated blade	Non-serrated blade
Rib	C, Ca, O, Cl, P, Na, Mg, Si, S, Sr, K, Fe	C, Ca, O, P, Na, Mg, S
Radius epiphysis	C, Ca, O, Na, P, S, Mg, Si	C, Ca, O, P, Na, S
Radius diaphysis	C, Ca, O, Mg, W, P, Fe	C, Ca, O, P, S, Na
Vertebra	C, Ca, O, Mg, P, Na, S	C, Ca, O, Fe, Na, Mg, Si, P, S, Cl, K, W
Carpal	C, Ca, O, Na, Al, Si, P, S, Mg	C, Ca, O, Na, Al, Si, P, S, Fe, Mg
Knife blade	C, Cr, O, Si, Al, Mo, Fe, Ti	C, Cr, O, Si, Al, Mo, Fe, Ti

Table 4




Figure 1

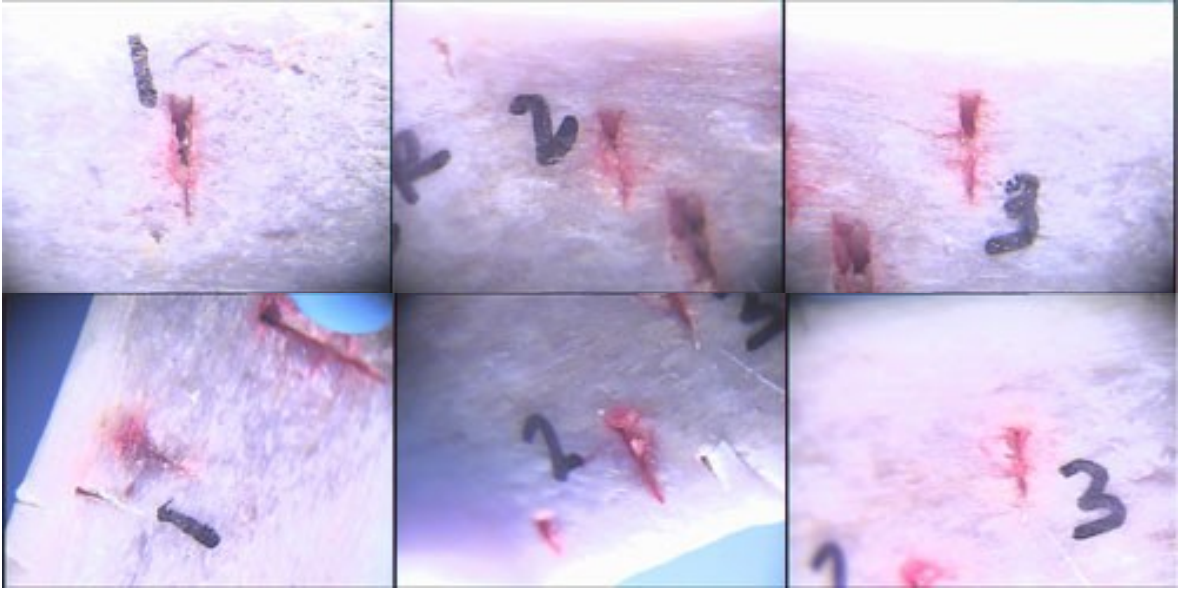


Figure 2


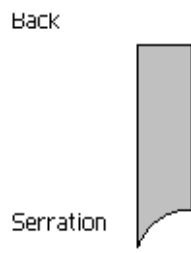


Figure 3

Serrated Knife



Sharp Knife

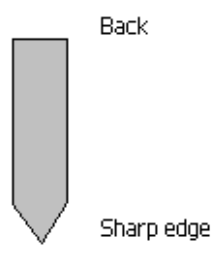


Figure 4